

The CU PAO: A Minimally Invasive, 2-Incision, Interlocking Periacetabular Osteotomy

Technique and Early Results

Omer Mei-Dan, MD, K. Linnea Welton, MD, Matthew J. Kraeutler, MD, David A. Young, MBBS, FRACS(Orth),
Sivashanmugam Raju, MD, and Tigran Garabekyan, MD

Investigation performed at the University of Colorado School of Medicine, Aurora, Colorado

Background: The aims of this study were to describe a novel minimally invasive, interlocking periacetabular osteotomy (PAO) for the treatment of hip dysplasia that was developed at our institution and to report on its safety, complications, and early clinical outcomes.

Methods: This was a prospective longitudinal study of the first 200 consecutive hips that underwent the CU (University of Colorado) PAO, an interlocking osteotomy combining the benefits of the Birmingham interlocking pelvic osteotomy (BIPO) and the Ganz PAO. The technique provides direct visualization of the sciatic nerve during the ischial osteotomy and allows for immediate weight-bearing postoperatively. Demographic characteristics, intraoperative and perioperative parameters, and functional outcomes were documented. All patients underwent hip arthroscopy 3 to 10 days prior to the PAO to address concomitant intra-articular pathology. Mechanical deep venous thrombosis (DVT) prophylaxis was used for 2 weeks postoperatively. Results were stratified to compare the first 100 and the second 100 cases.

Results: A total of 161 patients (200 hips) underwent primary PAO; mean follow-up was 20 months (range, 3 to 33 months). The mean patient age at the time of surgery was 29.4 years (range, 13 to 55 years). Females accounted for 89% of the patients included in this study. The average length of stay was 4 days. A concomitant proximal femoral derotational osteotomy was performed in 19 hips. The lateral center-edge angle (LCEA) improved from a mean of 18.8° preoperatively to 31.5° postoperatively ($p < 0.001$). The mean Non-Arthritic Hip Score (NAHS) improved from 56.0 preoperatively to 89.4 at the 24-month follow-up ($p < 0.0001$). Paresthesias in the distribution of the lateral femoral cutaneous nerve were common (65% at 2 weeks postoperatively) but resolved in 85% of the patients within the first 6 months. There were no sciatic nerve-related complications, deep infections, or DVTs.

Conclusions: The CU PAO enables corrective realignment of symptomatic acetabular dysplasia with direct visualization of the sciatic nerve, early weight-bearing, cosmetic incisions, and good short-term outcomes.

Level of Evidence: Therapeutic Level IV. See Instructions for Authors for a complete description of levels of evidence.

Acetabular dysplasia results in increased joint reactive forces, labral and articular cartilage hypertrophy and/or tearing, and progressive articular cartilage degeneration¹⁻⁵. Most patients with severe hip dysplasia experience symptomatic instability as a precursor to osteoarthritis. Periacetabular osteotomy (PAO) improves hip stability, delays or prevents the development of secondary osteoarthritis, and enhances patient function and activity⁶⁻¹⁴.

Ganz et al.⁹ developed the most widely used PAO technique (the Bernese PAO). Long-term results have shown that

the Bernese PAO is an effective treatment for symptomatic acetabular dysplasia¹³, although the technique has a steep learning curve, with the risk of major complications during the early learning period^{15,16}.

The Birmingham interlocking pelvic osteotomy (BIPO) was developed with the aim of improving the safety, efficacy, and reproducibility of PAO surgery while allowing for accelerated rehabilitation through early weight-bearing¹⁷. The BIPO involves interlocking step cuts for the ilium and a 2-incision approach with direct visualization and protection of the sciatic nerve.

Disclosure: The authors indicated that no external funding was received for any aspect of this work. On the **Disclosure of Potential Conflicts of Interest** forms, which are provided with the online version of the article, one or more of the authors checked "yes" to indicate that the author had a relevant financial relationship in the biomedical arena outside the submitted work (<http://links.lww.com/JBJS/F376>).

However, the BIPO does not aim to preserve the posterior column, and this may lead to greater rates of ischial nonunion¹⁷.

The senior author of the present study (O.M.-D.) has experience performing both the Bernese PAO and the BIPO and sought to combine the advantages of the 2 techniques. The CU (University of Colorado) PAO is a hybrid technique that combines the posterior column-preserving elements of the Bernese PAO with the interlocking, 2-incision approach of the BIPO, utilizing smaller cosmetic incisions¹⁵⁻¹⁷. The primary purpose of this study was to provide a description of the CU PAO technique and report on its safety and efficacy in achieving the desired correction, with the reporting of early clinical outcome data serving as a secondary aim.

Materials and Methods

Following institutional review board approval, we performed a prospective longitudinal cohort study of the first 200 patients treated with the CU PAO, between November 2015 and October 2018. All procedures were performed by the senior author (O.M.-D.), with the first 100 cases reflecting the learning curve with this technique. Inclusion criteria were (1)

persistent hip pain refractory to nonoperative management lasting at least 6 months, (2) reproducible clinical examination findings suggestive of intra-articular pain and instability, (3) a joint-space width of >2.5 mm on all radiographic views, and (4) radiographic findings consistent with frank or borderline hip dysplasia.

No patient with borderline hip dysplasia was offered a PAO as a first-line treatment option, although for the majority of these patients, hip arthroscopy alone, performed either by the senior author or another surgeon, had failed. Borderline dysplastic patients who exhibited substantial signs of instability (Beighton hypermobility score¹⁸ of >6, excessive femoral and/or acetabular version) were typically advised that the risk of failure of hip arthroscopy alone was high, although this was presented as a valid treatment option. When these patients elected to proceed with a PAO, hip arthroscopy was again performed prior to the PAO to address any new chondrolabral pathology that might have developed since the previous arthroscopic surgery.

Clinical diagnosis of acetabular dysplasia was determined according to accepted pathomorphologic signs and

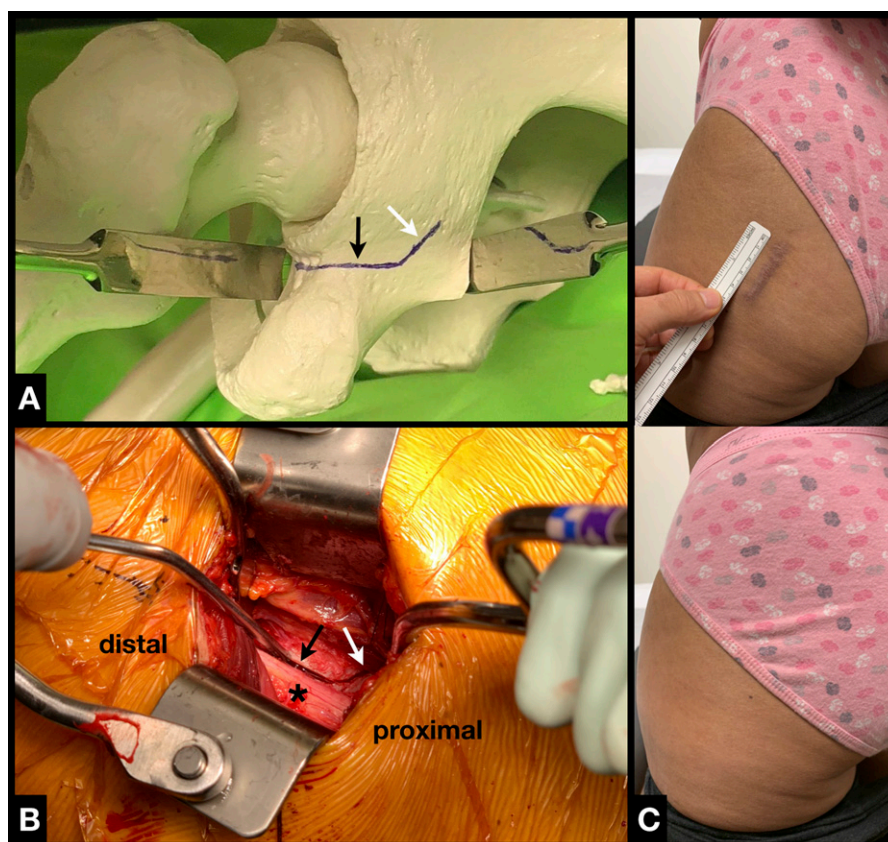


Fig. 1

Fig. 1-A Pelvic model demonstrating the location and trajectory of the ischial cut (blue line) with Lane retractors placed in the infracotyloid fossa (left) and greater sciatic notch (right). The ischial cut is initiated with a saw (black arrow) and extended proximally with a curved osteotome (white arrow). **Fig. 1-B** Intraoperative photograph demonstrating the posterior approach with the sciatic nerve (black asterisk) exposed and protected posteriorly. The ischial cut has been completed utilizing a saw (black arrow) and a curved osteotome (white arrow) to extend proximally while preserving the posterior column. **Fig. 1-C** Clinical photographs demonstrating the location and the cosmetic features of the posterior incision.

measurements¹⁹. History of hip pain, positive findings on provocative hip tests indicating a labral tear, radiographic evidence of hip dysplasia (lateral center-edge angle [LCEA] of $\leq 25^\circ$, sourcil angle of $\geq 10^\circ$), excessive acetabular version and/or femoral antetorsion, interruption of the Shenton line on the anteroposterior pelvic radiograph, and magnetic resonance imaging (MRI) findings of labral hypertrophy, articular cartilage thickening, or a ligamentum teres tear all aided in establishing a diagnosis of symptomatic hip instability^{3,20,21}. Patients selected for surgery underwent preoperative computed tomography (CT) and MRI to assess acetabular version, femoral torsion, and femoral-head sphericity as well as cartilage, labral, and subchondral bone integrity.

Surgical Technique

A detailed description of the CU PAO technique is provided in the Appendix. Briefly, the patient is placed in the lateral decubitus position and a 4 to 6-cm oblique incision is made in line with the gluteus maximus, with the surgeon's index fingers utilized to bluntly dissect the fibers and expose the perineural fat overlying the sciatic nerve. The sciatic nerve is mobilized posteriorly and Lane retractors are placed through the central interval in the short external rotators, directed proximally into the greater sciatic notch and distally into the infracotyloid fossa (Fig. 1-A). The ischial osseous cut is then initiated with an oscillating saw (Precision; Stryker), preserving 10 to 15 mm of posterior column. A curved osteotome is used to extend the

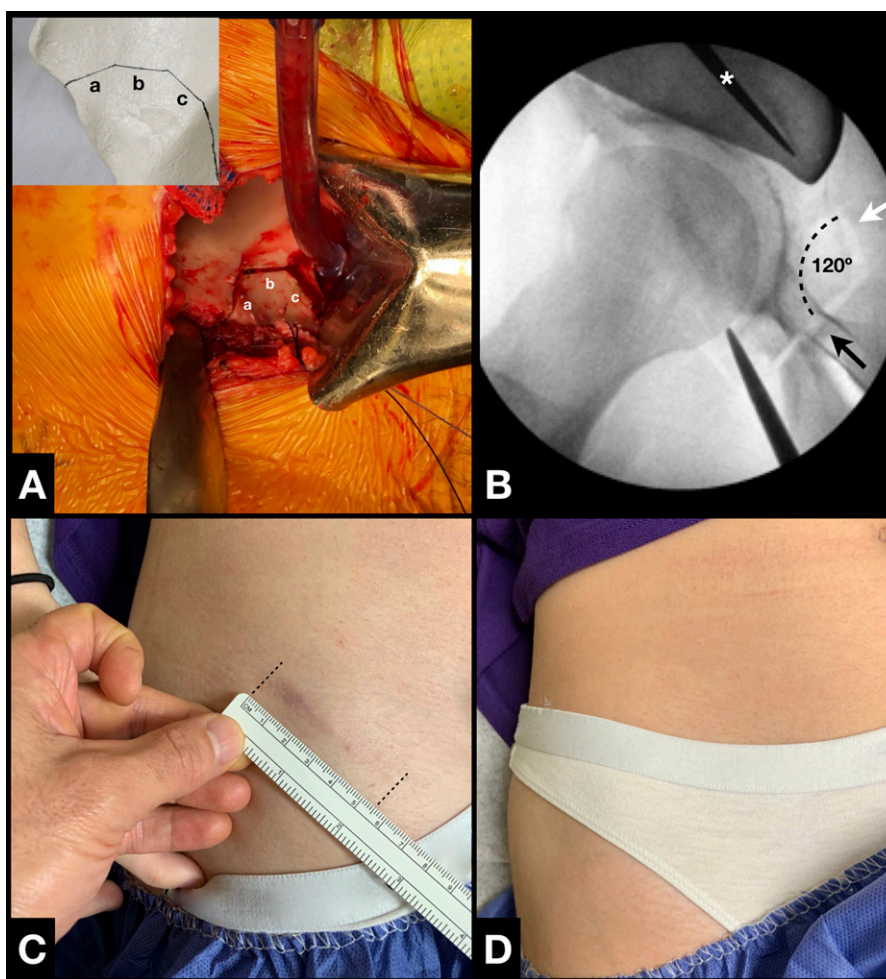


Fig. 2

Fig. 2-A Intraoperative photograph demonstrating the trajectory of the iliac step cuts (a, b, and c) with corresponding pelvic model representation (insert). **Fig. 2-B** False profile intraoperative fluoroscopic image allowing visualization of the posterior-column-preserving connecting osteotomy between the ilium and ischium. The descending cut along the posterior column, with osteotome in view (white asterisk), is performed through the anterior approach. This cut is aligned with the ascending cut along the posterior column (white arrow), performed through the posterior approach. The osteotome (white asterisk) penetrates only the inner cortex along the upper portion of the posterior column to complete the connecting osteotomy, thereby avoiding potential injury to the sciatic nerve. The transition angle (dashed black arc) subtended by the ischial osteotomy (black arrow) and the ascending cut along the posterior column (white arrow) is approximately 120° . **Figs. 2-C and 2-D** Clinical photographs demonstrating the location and the cosmetic features of the anterior incision.

bone cut 2 to 3 cm proximally (Fig. 1-B). The patient is then repositioned supine, preserving the original draping. A 4 to 6-cm oblique anterior incision is made 1 fingerbreadth distal to the iliac crest. The interval between the sartorius and tensor fasciae latae (TFL) is developed just distal to the anterior superior iliac spine (ASIS), and the dissection is extended proximally along the iliac crest. The hip is flexed to 70° to relax the iliopsoas, and an angled crescentic osteotome is advanced subperiosteally under the hip flexor, along the superior cortex of the pubic root. Fluoroscopic views are obtained to position the osteotome approximately 5 mm medial to the medial teardrop, angled laterally to complete the inferior aspect of the pubic cut just medial to the medial border of the teardrop. A sciatic notch retractor is then placed in the inner pelvis, and the iliac step cuts are made in accordance with the desired degree of lateral correction (Fig. 2-A)¹⁷. A modification is made to the posterior iliac cut, which is directed inferiorly to preserve the posterior column (Fig. 2-B). The iliac cut is then connected to the proximal aspect of the ischial cut under fluoroscopic visualization to complete the osteotomy and mobilize the central acetabular fragment (CAF). The corrective maneuver is then performed and stabilized as previously described¹⁷. Screws are typically removed after osseous union is achieved (Fig. 3).

All patients underwent routine hip arthroscopy 3 to 10 days prior to the PAO to address intra-articular pathology. Hip arthroscopy was performed prior to PAO (rather than during the same anesthesia session) in order to (1) avoid prolonged anesthesia time, (2) avoid the seepage of fluid from hip arthroscopy into the surgical field during the PAO, (3) reduce the rate of capsulolabral adhesions²²⁻²⁴ by enabling stationary bicycle use prior to PAO, and (4) allow the surgeon and patient to discuss the possibility of opting out of the PAO if substantial articular cartilage damage was identified during arthroscopy. If microfracture was not performed during hip arthroscopy, patients were cleared for weight-bearing as tolerated with the use of crutches before hospital discharge, after a post-mobilization radiograph was made. Mechanical deep venous thrombosis (DVT) prophylaxis (ActiveCare) was used for 2 weeks postoperatively in addition to aspirin (81 mg, once daily)²⁵.

Outcome Measures

All patients enrolled in the study completed preoperative questionnaires and detailed demographic data sheets. Data collected included age, sex, height, weight, and body mass index (BMI) as well as preoperative values for outcomes of

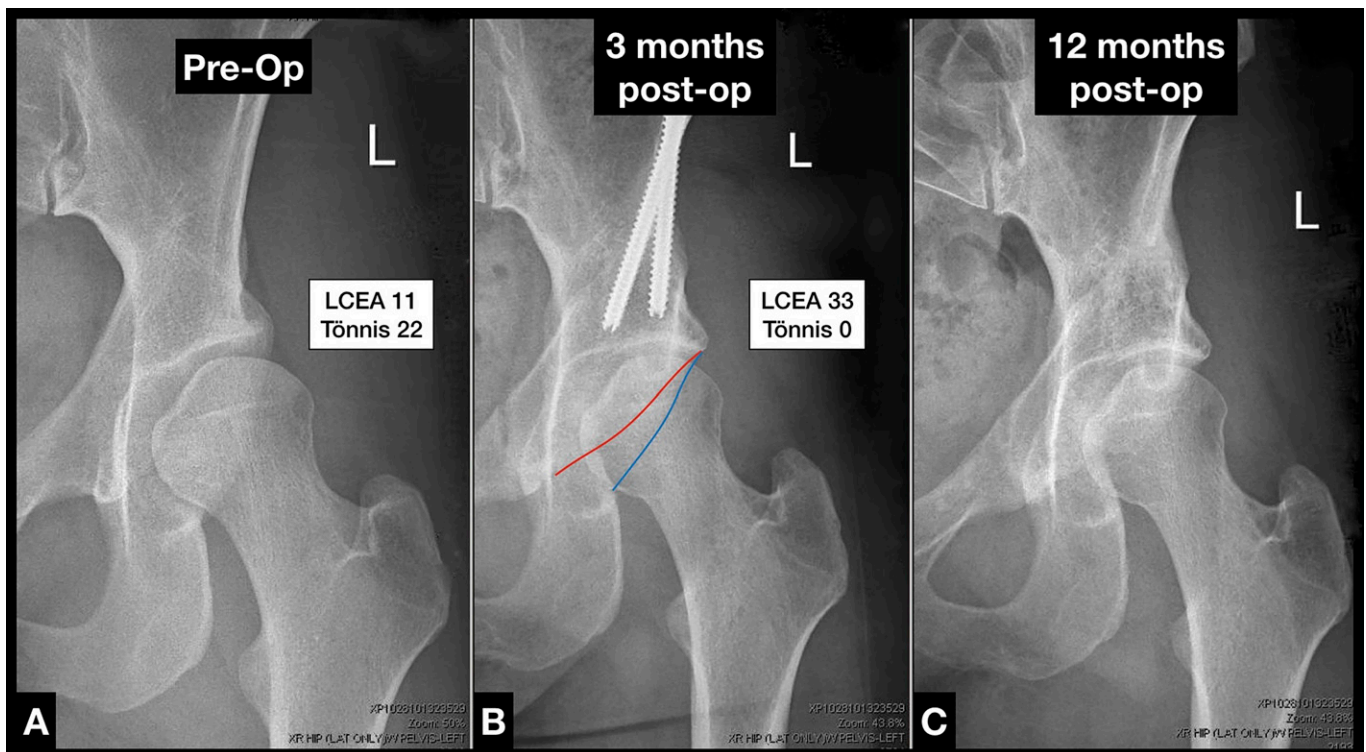


Fig. 3

Fig. 3-A Preoperative anteroposterior pelvic radiograph cropped about the left hip demonstrating severe dysplasia. LCEA = lateral center-edge angle, and Tönnis = sourcil angle (in degrees). **Fig. 3-B** Three-month postoperative anteroposterior pelvic radiograph cropped about the left hip following corrective osteotomy. Note the improved lateral coverage as well as the alignment demonstrated in the anterior (red) and posterior (blue) acetabular wall relationship. LCEA = lateral center-edge angle, and Tönnis = sourcil angle (in degrees). **Fig. 3-C** Twelve-month postoperative anteroposterior pelvic radiograph cropped about the left hip following corrective osteotomy. Screws have been removed following complete osseous healing.

TABLE I Patient Demographics*

Age (yr)	29.4 ± 10.0 (13 to 55)
Right hip (%)	55.6
Female sex (%)	89
Height (cm)	166.8 ± 8.4
Weight (kg)	66.7 ± 12.4
BMI (kg/m ²)	23.9 ± 4.1 (16.7 to 36.4)
Duration of pain at initial presentation (yr)	4.23 ± 4.6 (0.5 to 20)
Laxity (Beighton hypermobility score)	3.7 ± 2.5
Tönnis grade	0.2 ± 0.6
Sharp angle (°)	45.0 ± 3.8 (36 to 55)
Lateral center-edge angle (°)	18.8 ± 6.9 (−11 to 32)
Sourcil (Tönnis angle) (°)	12.1 ± 6.5 (0 to 39)
Lateral joint-space width (mm)	4.7 ± 0.9 (2.9 to 7.4)
Medial joint-space width (mm)	4.3 ± 1.0 (2.9 to 8.1)
Acetabular equatorial version (°)	22.3 ± 5.0 (9 to 37)
Femoral torsion (°)	18.6 ± 9.1 (−12 to 56)
dGEMRIC (coronal) (msec)	421.1 ± 98 (231 to 643)
dGEMRIC (sagittal) (msec)	398.5 ± 106 (205 to 684)
Broken Shenton line (%)	24%

*Continuous data are given as the mean and standard deviation, with the range in parentheses, and categorical data are given as the percentage. dGEMRIC = delayed gadolinium-enhanced MRI of cartilage.

interest. The following characteristics were recorded prospectively: intraoperative blood loss, requirement for blood transfusion, hospital length of stay, anesthesia type, and operative time. We also recorded major complications (loss of correction, intra-articular osteotomy, sciatic nerve injury, pulmonary embolism [PE]) and minor complications (transient neurapraxia, heterotopic ossification, iatrogenic fractures of the posterior column, superficial skin infection, DVT). The primary functional outcome measure was the Non-Arthritic Hip Score (NAHS).

Statistical Analysis

The mean and standard deviation were calculated for all continuous variables. Categorical data are presented as a percentage of the entire study population. A paired sample t test was used to compare radiographic parameters from preoperatively to postoperatively. A p value of <0.05 was considered significant.

Results

Overall, 161 patients (200 hips) underwent a CU PAO, with 19 hips undergoing a concomitant proximal femoral derotational osteotomy. Five revision PAOs, in which the index surgery was performed by another surgeon, were excluded. The mean follow-up was 20 months (range, 3 to 33 months). The

mean patient age at the time of surgery was 29.4 years (range, 13 to 55 years); 89% of the patients were female (Table I).

The mean incision length was 4.5 cm posteriorly (range, 3.5 to 6.0 cm) and 6 cm anteriorly (range, 5.0 to 7.5 cm). Mean blood loss was 579 ± 402 mL (range, 185 to 1,900 mL), with a mean 50% blood salvage. The mean hemoglobin concentration decreased from 13.7 g/dL preoperatively to 10.1 g/dL on postoperative day (POD) 1 and 9.1 g/dL on POD 3 (Table II), with only 7% of the patients requiring allogeneic blood transfusion. The average time to discharge was 4.5 ± 1.0 days when epidural anesthesia was used (55% of the cases) and 3.5 ± 1.0 days when spinal anesthesia was used. The average operative time was 3.2 hours (range, 2.2 to 4.5 hours).

The LCEA and Tönnis angle both significantly improved from preoperatively to radiographic follow-up (p < 0.001) (Table III). The most common concomitant procedures performed during hip arthroscopy (prior to the PAO) were labral repair (89%), cam resection (82%), and microfracture of the acetabulum (42%).

TABLE II Hemoglobin Concentration and Bleeding and Transfusion Information*

Hemoglobin concentration (g/dL)	
Preop.	13.67 ± 1.56
Postop. day 1	10.13 ± 1.35
Postop. day 2	9.38 ± 1.42
Postop. day 3	9.13 ± 1.40
Intraop. bleeding (mL)	
Overall	579 ± 402
1st 100 cases	667
2nd 100 cases	492
Blood salvage (mL)	292.39 ± 195.51
% of patients requiring transfusion	7

*Continuous data are given as the mean and standard deviation; categorical data are given as the percentage.

TABLE III Radiographic Parameters*

	Preop.	Follow-up	P Value
Lateral center-edge angle (°)	18.8 ± 6.9	31.5 ± 5.9	<0.001
Sourcil (Tönnis angle) (°)	12.0 ± 6.5	0.6 ± 4.2	<0.001
Internal rotation (at 90° of hip flexion)(°)	29.3 ± 14.8	17.3 ± 7.7	<0.001
Neck axis distance (NAD) (mm)	16.2 ± 5.8	8.9 ± 5.3	<0.001

*The values are given as the mean and standard deviation.

TABLE IV Postoperative Complications

	No. (%)
Major complications	
Hardware failure requiring refixation	2 (1.0)
Intra-articular osteotomy	1 (0.5)
Pulmonary embolism	0
Sciatic nerve injury	0
Minor complications	
Lateral femoral cutaneous nerve transient neurapraxia	130 (65)
Posterior column fracture (nondisplaced)	5 (2.5)
Heterotopic ossification	4 (2.0)
Superficial infection	4 (2.0)
Obturator nerve transient neurapraxia	3 (1.5)
Pubic ramus fibrous union	2 (1.0)
Deep infection	0
Deep venous thrombosis	0

NAHS scores showed significant improvement, from 56.0 ± 17.9 preoperatively to 81.2 ± 15.3 at 6 months of follow-up ($p < 0.0001$). Scores also improved significantly from 6 to 12 months (87.3 ± 11.9) ($p < 0.01$), and continued to improve from 12 to 24 months of follow-up (89.4 ± 8.9) but not to a significant extent ($p = 0.11$).

Overall, major complications were seen in 3 (1.5%) of the cases and minor complications, in 38 (19.0%) of the cases

(Table IV). Two patients from the first 30 cases (during the development of the technique) experienced postoperative hardware loosening with resultant loss of correction requiring refixation. Paresthesias in the distribution of the lateral femoral cutaneous nerve (LFCN) were common (65% at 2 weeks postoperatively) but resolved in 85% of the patients within the first 6 months. There were no sciatic nerve-related complications. There was 1 inadvertent intra-articular osteotomy involving the inferior region of the acetabulum during the ischial osteotomy, with no overall effect on postoperative protocol or surgical outcome.

Discussion

The results of our study demonstrated that the CU PAO allows for accurate, reproducible, and safe correction of symptomatic acetabular dysplasia, even during the surgeon's learning curve of the technique. This technique aims to combine beneficial elements of the Bernese PAO and the BIPO.

The learning curve is an important consideration for any PAO technique. Burke et al.⁷ performed a retrospective review of their first 85 Bernese PAOs and observed that, over the 7-year study duration, mean blood loss and operative time decreased from 2,000 to 900 mL and from 4 hours to 2 hours, respectively. Our study spanned 3 years, with a mean blood loss of approximately 670 mL during the first 100 cases and 500 mL during the second 100 cases. Operative time, which included closing both mini-incisions and the transition of the patient from the lateral to supine positions, averaged 3 hours but

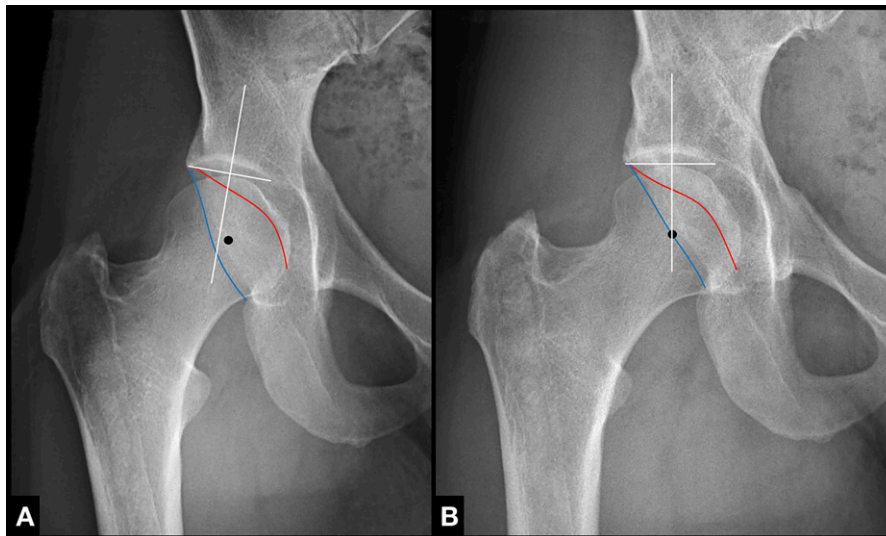


Fig. 4

Fig. 4-A Preoperative anteroposterior pelvic radiograph cropped about the right hip demonstrating acetabular dysplasia exhibiting both anterior and lateral undercoverage. The anterior (red) and posterior (blue) wall relationship is outlined in addition to the axis of the sourcil (white orthogonal lines). Note that the center of the femoral head (black circle) lies medial to the orthogonal sourcil axis. **Fig. 4-B** Postoperative anteroposterior radiograph cropped about the right hip demonstrating corrected acetabular alignment with improved anterior and lateral coverage. The anterior (red) and posterior (blue) wall relationship is outlined once again. Note the horizontally positioned sourcil (white orthogonal lines) that provides balanced coverage of the femoral head center (black circle). This female patient previously underwent hip arthroscopy and derotational femoral osteotomy but experienced continued symptomatic instability that was successfully addressed with the CU PAO procedure.

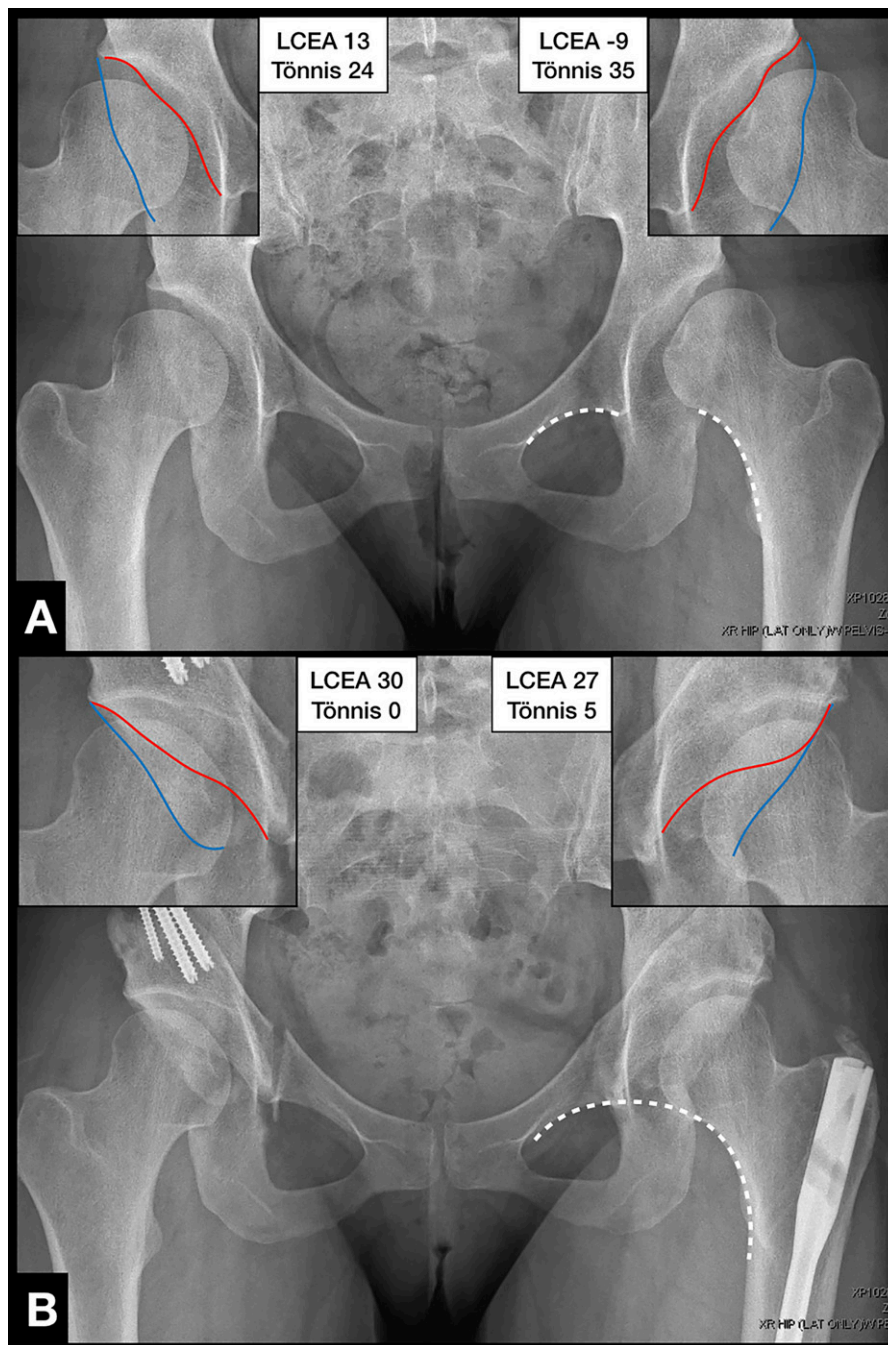


Fig. 5

Fig. 5-A Preoperative anteroposterior pelvic radiograph demonstrating severe acetabular dysplasia of bilateral hips. The anterior (red) and posterior (blue) wall relationship is outlined, demonstrating severely deficient anterior and lateral coverage (inserts). The Shenton line is broken on the left hip (dashed white line). LCEA = lateral center edge angle, Tönnis = sourcil angle (in degrees). **Fig. 5-B** Postoperative anteroposterior pelvic radiograph at the 12-month follow-up of the left hip (periacetabular osteotomy [PAO], derotational femoral osteotomy, and screw removal) and 3-month follow-up of the right hip (PAO). The improved anterior (red) and posterior (blue) wall relationship is outlined (inserts). The Shenton line is restored on the left hip (dashed white line). LCEA = lateral center edge angle, Tönnis = sourcil angle (in degrees).

included additional steps, such as using an intraoperative flat plate to fine-tune and precisely define the correction (Fig. 4) as well as ASIS reduction to preserve flexion and avoid the “double-bump” deformity anteriorly.

The CU PAO technique achieved comparable correction to the BIPO and Bernese PAO techniques, with significant improvement in outcome scores also demonstrated. In the study by Burke et al.⁷, the mean LCEA improved from 5° to 21°

TABLE V Pros and Cons of the Bernese PAO, BIPO, and CU PAO*

	Bernese PAO	BIPO	CU PAO
Pros			
Maintains posterior column	+	—	+
Immediate weight-bearing	—	+	+
Direct visualization of sciatic nerve	—	+	+
Direct visualization of ischium for osteotomy	—	+	+
Cons			
Risk of intra-articular osteotomy/fracture	Yes	Low	Low
Risk of ischial nonunion	Low	Yes	Low
Risk of sciatic nerve palsy	Moderate	Low	Low
Use of fluoroscopy for ischial cut	Yes	No	No
Scar cosmesis	—	+	+

*PAO = periacetabular osteotomy, BIPO = Birmingham interlocking pelvic osteotomy, and CU = University of Colorado.

in anteverted hips and from 9° to 30° in neutral or retroverted hips ($p < 0.0001$). The correction achieved with our technique was also significant, with the mean LCEA improving from 18.8° preoperatively to 31.5° at the time of follow-up. Furthermore, our outcome scores showed significant improvement, with an average postoperative NAHS score of 89 at 2 years (a nearly 40% increase from the mean preoperative value). Burke et al.⁷ also reported significant improvement in functional outcomes scores, with a final mean Merle d'Aubigné-Postel hip score of 16 (close to 20% improvement). Similarly, with use of the BIPO technique, a median Harris Hip Score of 90.5 at final postoperative follow-up was achieved (an approximate 40% increase compared with preoperative values)¹⁷.

The extent of acetabular realignment achieved with the CU PAO technique is in keeping with the radiographic correction found with the Bernese PAO, BIPO, and other described pelvic and periacetabular osteotomies^{7,9,13,17,26,27}. It is important for any new PAO technique to demonstrate the ability to accommodate large osseous corrections, as may be necessary for patients with an LCEA of $\leq 10^\circ$ (Table I, Fig. 5). In our study, 29 hips fit into this category, with a mean preoperative LCEA of 4.0°, which improved to 24.4°. These were the most difficult cases, each involving a severely hypovolemic acetabulum and necessitating a balanced correction while maintaining physiologic hip range of motion. Many of these cases required a concomitant femoral osteotomy.

Clinically important postoperative complications following the CU PAO were rare. No patient required an unplanned reoperation after the initial 100-patient learning curve. Only 2 patients (1%, both within the first 30 cases) required refixation, as initially only 2 rather than 3 or 4 stabilizing screws were utilized.

This is less than the reoperation rate following PAO (3%) that was recently reported by the Academic Network of Conservational Hip Outcomes Research (ANCHOR) Group²⁶. Furthermore, the major complication rate of 1.5% reported in the present study is substantially lower than the 7% rate reported by the ANCHOR Group²⁶. While transient neurapraxia of the LFCN was common, no sciatic nerve injury was encountered. The incidence of sciatic nerve injury following PAO has been reported to be 1% to 5%²⁸⁻³⁰. Some authors even cite these rates of nerve injury to be a “best-case scenario” given that they represented data from experienced surgeons reviewed retrospectively for injuries that were important enough to have warranted early diagnoses³⁰. From their experience performing their first 70 Bernese PAOs, Davey and Santore¹⁵ reported an overall complication rate of 71%, with 14% classified as major complications. Siebenrock et al.³¹ reported a major complication in 18 (24%) of their first 75 PAO cases, including intra-articular cuts, loss of correction, and femoral-head subluxation. For the first 100 BIPO cases, a complication rate of 10.4% was previously reported, with 41.6% of the cases with complications requiring reoperation¹⁷.

There are benefits to the CU PAO (Table V). With regard to surgical approach, by beginning with a small posterior incision, the surgeon has direct visualization of the sciatic nerve. The nerve can be gently retracted and protected throughout the entire ischial cut (Fig. 1-B), which eliminates the need for neural monitoring. Proximally, the ischial cut is angled cephalad to preserve the posterior column, making the subsequent connection of the iliac and ischial osteotomies simpler, as only the inner cortex needs to be cut while the sciatic nerve is not directly visualized. Furthermore, by utilizing this posterior incision initially, the anterior incision can be made smaller than that described for the Bernese technique^{9,31}. The typical anterior incision in our PAO technique is 6 cm in length and does not cross the hip flexion crease. This is substantially smaller than the 15 to 20-cm incision in the original Ganz description, which has evolved to a 10 to 12-cm modified Smith-Petersen approach²⁸.


The CU PAO, similar to the Bernese PAO, maintains the posterior column, which reduces the risk of ischial nonunion and improves mechanical stability when compared with the BIPO^{9,17}. The Bernese PAO utilizes a single osteotomy line along the ilium, anterior to posterior, transitioning sharply to descend along the posterior column to meet the ischial osteotomy. Upon corrective realignment, the superior weight-bearing zone of the realigned construct relies on point loading across a flat superior portion of the ilium and may preclude immediate full weight-bearing postoperatively³². The CU PAO increases osseous contact in the weight-bearing zone of the realigned fragment via a 3-step iliac osteotomy, allowing immediate full weight-bearing postoperatively. However, at present, we are lacking in basic science studies investigating the biomechanical stability of either construct, and therefore, this is only a theoretical advantage. Additionally, the CU PAO creates a larger, 120°, transition angle between the ischial and iliac osteotomies (Fig. 2-B) as compared with the 90° angle in the Bernese PAO, facilitating an easier mobilization and rotation of the central acetabular fragment^{33,34}.

The limitations of this study should be noted. This was a case series of patients treated by a single surgeon who specializes in hip preservation. Thus, the generalizability of our findings may be limited. Second, our findings represent early results of the CU PAO (mean follow-up of 20 months). The outcome assessments are subject to detection bias. While the clinical and functional outcomes are promising^{7,27}, longer-term follow-up with blinded outcome assessment will be important to assess the longevity of the procedure.

Conclusions

The CU PAO enables corrective realignment of symptomatic acetabular dysplasia with direct visualization of the sciatic nerve, early weight-bearing, cosmetic incisions, and a good short-term outcome.

Appendix

 Supporting material provided by the authors is posted with the online version of this article as a data supplement at [jbjs.org \(http://links.lww.com/JBJS/F377\)](http://links.lww.com/JBJS/F377). ■

NOTE: The authors thank Mr. Jesse A. Goodrich, BA, for assistance with the statistical analysis for this study.

Omer Mei-Dan, MD¹
K. Linnea Welton, MD²

Matthew J. Kraeutler, MD³
David A. Young, MBBS, FRACS(Orth)⁴
Sivashanmugam Raju, MD⁵
Tigran Garabekyan, MD⁶

¹Department of Orthopedics, University of Colorado School of Medicine, Aurora, Colorado

²Hip Preservation and Sports Surgery, MultiCare Health System, Auburn, Washington

³Department of Orthopaedic Surgery, St. Joseph's University Medical Center, Paterson, New Jersey

⁴Melbourne Orthopaedic Group, Melbourne, Victoria, Australia

⁵Department of Pediatric Orthopedic Surgery, St. Louis University School of Medicine, St. Louis, Missouri

⁶Southern California Hip Institute, North Hollywood, California

E-mail address for O. Mei-Dan: omer.meidan@ucdenver.edu

ORCID iD for O. Mei-Dan: [0000-0001-7555-986X](https://orcid.org/0000-0001-7555-986X)

ORCID iD for K.L. Welton: [0000-0002-8363-5647](https://orcid.org/0000-0002-8363-5647)

ORCID iD for M.J. Kraeutler: [0000-0002-2276-7814](https://orcid.org/0000-0002-2276-7814)

ORCID iD for D.A. Young: [0000-0001-9947-6655](https://orcid.org/0000-0001-9947-6655)

ORCID iD for S. Raju: [0000-0002-0331-107X](https://orcid.org/0000-0002-0331-107X)

ORCID iD for T. Garabekyan: [0000-0002-5021-9620](https://orcid.org/0000-0002-5021-9620)

References

- Crawford MJ, Dy CJ, Alexander JW, Thompson M, Schroder SJ, Vega CE, Patel RV, Miller AR, McCarthy JC, Lowe WR, Noble PC. The 2007 Frank Stinchfield Award. The biomechanics of the hip labrum and the stability of the hip. *Clin Orthop Relat Res*. 2007 Dec;(465):16-22.
- Ganz R, Parvizi J, Beck M, Leunig M, Nötzli H, Siebenrock KA. Femoroacetabular impingement: a cause for osteoarthritis of the hip. *Clin Orthop Relat Res*. 2003 Dec;(417):112-20.
- Garabekyan T, Ashwell Z, Chadayammuri V, Jesse MK, Pascual-Garrido C, Petersen B, Mei-Dan O. Lateral acetabular coverage predicts the size of the hip labrum. *Am J Sports Med*. 2016 Jun;44(6):1582-9. Epub 2016 Mar 17.
- Hartig-Andreasen C, Søballe K, Troelsen A. The role of the acetabular labrum in hip dysplasia. A literature overview. *Acta Orthop*. 2013 Feb;84(1):60-4. Epub 2013 Jan 23.
- James S, Miocevic M, Malara F, Pike J, Young D, Connell D. MR imaging findings of acetabular dysplasia in adults. *Skeletal Radiol*. 2006 Jun;35(6):378-84. Epub 2006 Mar 29.
- Clohisey JC, Barrett SE, Gordon JE, Delgado ED, Schoenecker PL. Periacetabular osteotomy in the treatment of severe acetabular dysplasia. Surgical technique. *J Bone Joint Surg Am*. 2006 Mar;88(Suppl 1 Pt 1):65-83.
- Burke NG, Devitt BM, Baker JF, Butler JS, Cousins G, McCormack D, O'Byrne JM. Outcome of periacetabular osteotomy for the management of acetabular dysplasia: experience in an academic centre. *Acta Orthop Belg*. 2011 Feb;77(1):33-40.
- Clohisey JC, Schutz AL, St John L, Schoenecker PL, Wright RW. Periacetabular osteotomy: a systematic literature review. *Clin Orthop Relat Res*. 2009 Aug;467(8):2041-52. Epub 2009 Apr 21.
- Ganz R, Klaue K, Vinh TS, Mast JW. A new periacetabular osteotomy for the treatment of hip dysplasias. Technique and preliminary results. *Clin Orthop Relat Res*. 1988 Jul;(232):26-36.
- Hingsammer AM, Kalish LA, Stelzeneder D, Bixby S, Mamisch TC, Connell P, Millis MB, Kim YJ. Does periacetabular osteotomy for hip dysplasia modulate cartilage biochemistry? *J Bone Joint Surg Am*. 2015 Apr 1;97(7):544-50.
- Leunig M, Siebenrock KA, Ganz R. Rationale of periacetabular osteotomy and background work. *Instr Course Lect*. 2001;50:229-38.
- Ninomiya S. Rotational acetabular osteotomy for the severely dysplastic hip in the adolescent and adult. *Clin Orthop Relat Res*. 1989 Oct;(247):127-37.
- Stappacher SD, Tannast M, Ganz R, Siebenrock KA. Mean 20-year followup of Bernese periacetabular osteotomy. *Clin Orthop Relat Res*. 2008 Jul;466(7):1633-44. Epub 2008 May 1.
- Trousdale RT, Ekkernkamp A, Ganz R, Wallrichs SL. Periacetabular and intertrochanteric osteotomy for the treatment of osteoarthritis in dysplastic hips. *J Bone Joint Surg Am*. 1995 Jan;77(1):73-85.
- Davey JP, Santore RF. Complications of periacetabular osteotomy. *Clin Orthop Relat Res*. 1999 Jun;(363):33-7.
- Espinosa N, Strassberg J, Belzile EL, Millis MB, Kim YJ. Extraarticular fractures after periacetabular osteotomy. *Clin Orthop Relat Res*. 2008 Jul;466(7):1645-51. Epub 2008 May 9.
- Mei-Dan O, Jewell D, Garabekyan T, Brockwell J, Young DA, McBryde CW, O'Hara JN. The Birmingham interlocking pelvic osteotomy for acetabular dysplasia: 13- to 21-year survival outcomes. *Bone Joint J*. 2017 Jun;99-B(6):724-31.
- Beighton P, Horan F. Orthopaedic aspects of the Ehlers-Danlos syndrome. *J Bone Joint Surg Br*. 1969 Aug;51(3):444-53.
- Kraeutler MJ, Garabekyan T, Pascual-Garrido C, Mei-Dan O. Hip instability: a review of hip dysplasia and other contributing factors. *Muscles Ligaments Tendons J*. 2016 Dec 21;6(3):343-53.
- Kraeutler MJ, Ashwell ZR, Garabekyan T, Goodrich JA, Welton KL, Flug JA, O'Hara JN, Mei-Dan O. The iliofemoral line: a radiographic sign of acetabular dysplasia in the adult hip. *Am J Sports Med*. 2017 Sep;45(11):2493-500. Epub 2017 Jun 13.
- Chadayammuri V, Garabekyan T, Bedi A, Pascual-Garrido C, Rhodes J, O'Hara J, Mei-Dan O. Passive hip range of motion predicts femoral torsion and acetabular version. *J Bone Joint Surg Am*. 2016 Jan 20;98(2):127-34.
- Locks R, Bolia I, Utsunomiya H, Briggs K, Philippon MJ. Current concepts in revision hip arthroscopy. *Hip Int*. 2018 Jul;28(4):343-51. Epub 2018 May 16.
- Locks R, Bolia IK, Utsunomiya H, Briggs KK, Philippon MJ. Revision hip arthroscopy after labral reconstruction using iliotibial band autograft: surgical findings and comparison of outcomes with labral reconstructions not requiring revision. *Arthroscopy*. 2018 Apr;34(4):1244-50. Epub 2018 Feb 15.
- Woodward RM, Philippon MJ. Persistent or recurrent symptoms after arthroscopic surgery for femoroacetabular impingement: a review of imaging findings. *J Med Imaging Radiat Oncol*. 2019 Feb;63(1):15-24. Epub 2018 Oct 27.

- 25.** Kraeutler MJ, Raju S, Garabekyan T, Mei-Dan O. Incidence of deep venous thrombosis following periacetabular and derotational femoral osteotomy: a case for mechanical prophylaxis. *J Hip Preserv Surg.* 2018 Mar 5;5(2):119-24.
- 26.** Clohisy JC, Ackerman J, Baca G, Baty J, Beaulé PE, Kim YJ, Millis MB, Podeszwa DA, Schoenecker PL, Sierra RJ, Sink EL, Sucato DJ, Trousdale RT, Zaltz I. Patient-reported outcomes of periacetabular osteotomy from the prospective ANCHOR cohort study. *J Bone Joint Surg Am.* 2017 Jan 4;99(1):33-41.
- 27.** Khan OH, Malviya A, Subramanian P, Agolley D, Witt JD. Minimally invasive periacetabular osteotomy using a modified Smith-Petersen approach: technique and early outcomes. *Bone Joint J.* 2017 Jan;99-B(1):22-8.
- 28.** Peters CL, Erickson JA, Hines JL. Early results of the Bernese periacetabular osteotomy: the learning curve at an academic medical center. *J Bone Joint Surg Am.* 2006 Sep;88(9):1920-6.
- 29.** Pring ME, Trousdale RT, Cabanela ME, Harper CM. Intraoperative electromyographic monitoring during periacetabular osteotomy. *Clin Orthop Relat Res.* 2002 Jul;(400):158-64.
- 30.** Sierra RJ, Beaulé P, Zaltz I, Millis MB, Clohisy JC, Trousdale RT; ANCHOR group. Prevention of nerve injury after periacetabular osteotomy. *Clin Orthop Relat Res.* 2012 Aug;470(8):2209-19. Epub 2012 Jun 9.
- 31.** Siebenrock KA, Schöll E, Lottenbach M, Ganz R. Bernese periacetabular osteotomy. *Clin Orthop Relat Res.* 1999 Jun;(363):9-20.
- 32.** Kamath AF. Bernese periacetabular osteotomy for hip dysplasia: surgical technique and indications. *World J Orthop.* 2016 May 18;7(5):280-6.
- 33.** Hüssell JG, Mast JW, Mayo KA, Howie DW, Ganz R. A comparison of different surgical approaches for the periacetabular osteotomy. *Clin Orthop Relat Res.* 1999 Jun;(363):64-72.
- 34.** Hüssell JG, Rodriguez JA, Ganz R. Technical complications of the Bernese periacetabular osteotomy. *Clin Orthop Relat Res.* 1999 Jun;(363):81-92.